



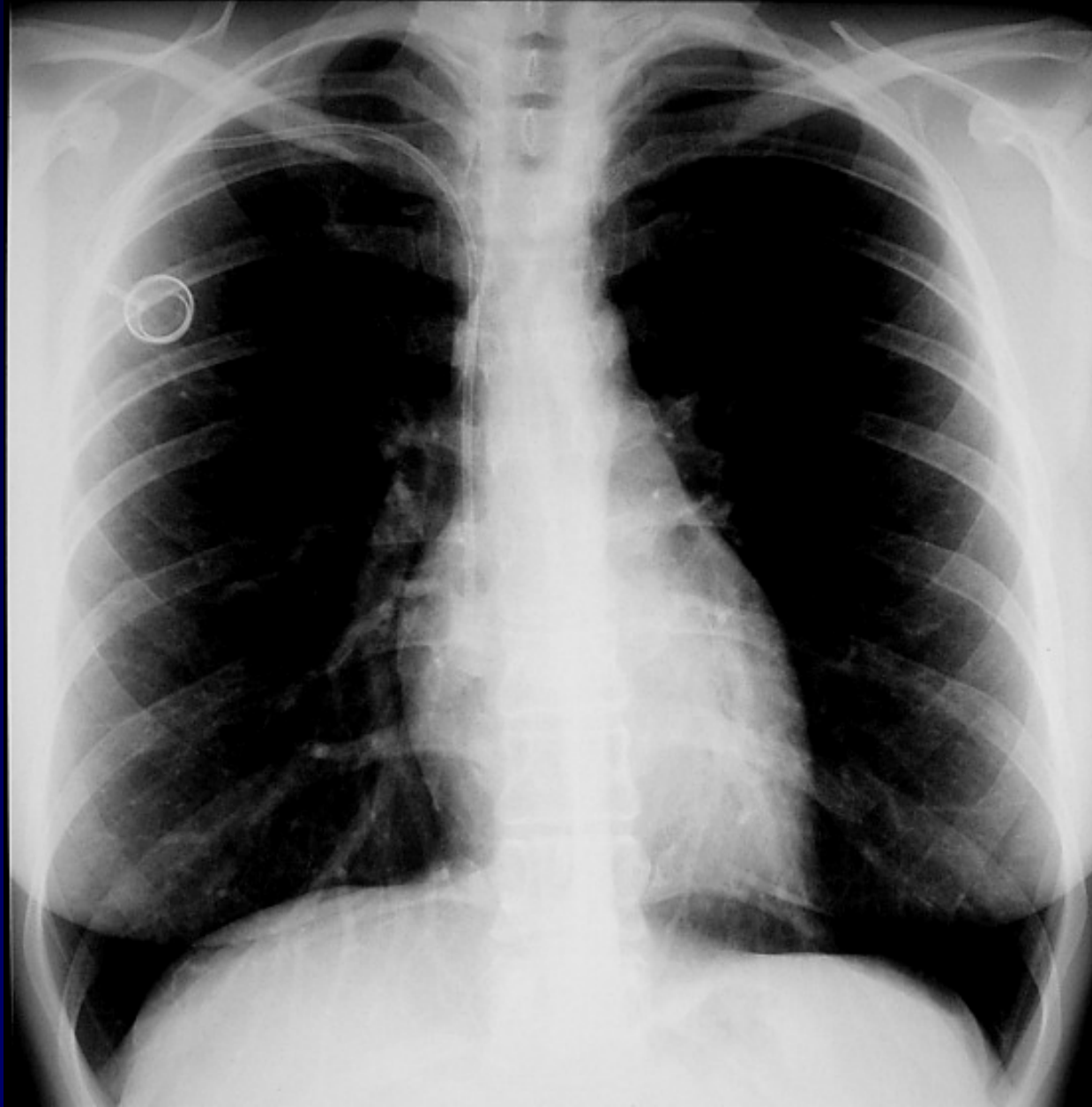## **Dossier 4**

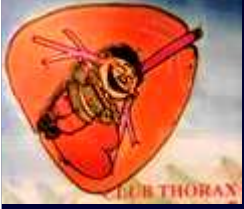**P. LACOMBE**  
**M. EL HAJJAM**

**Femme de 28 ans**

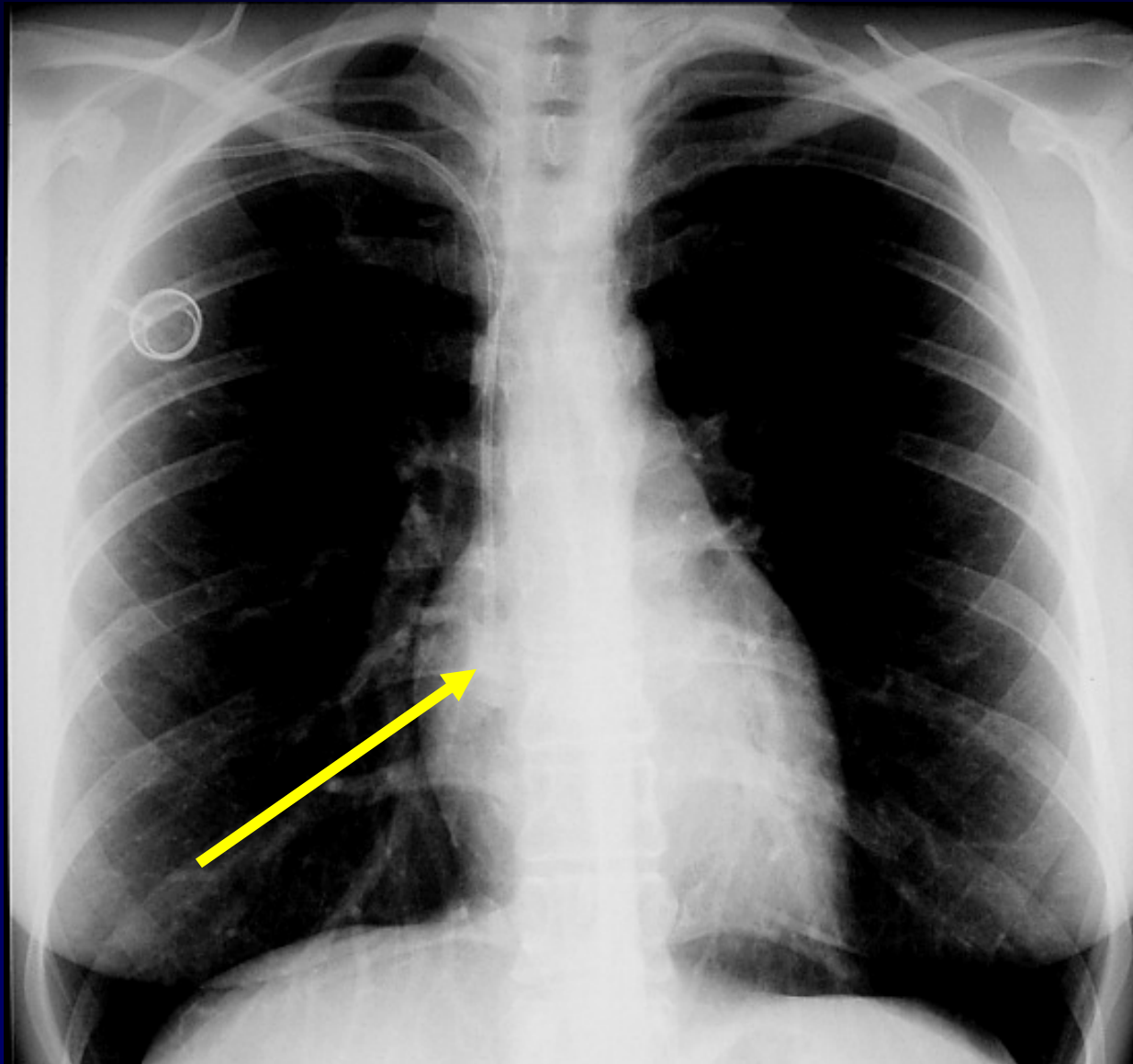
**Mélanome temporal gauche métastatique**

**Radio thorax et TDM de suivi**

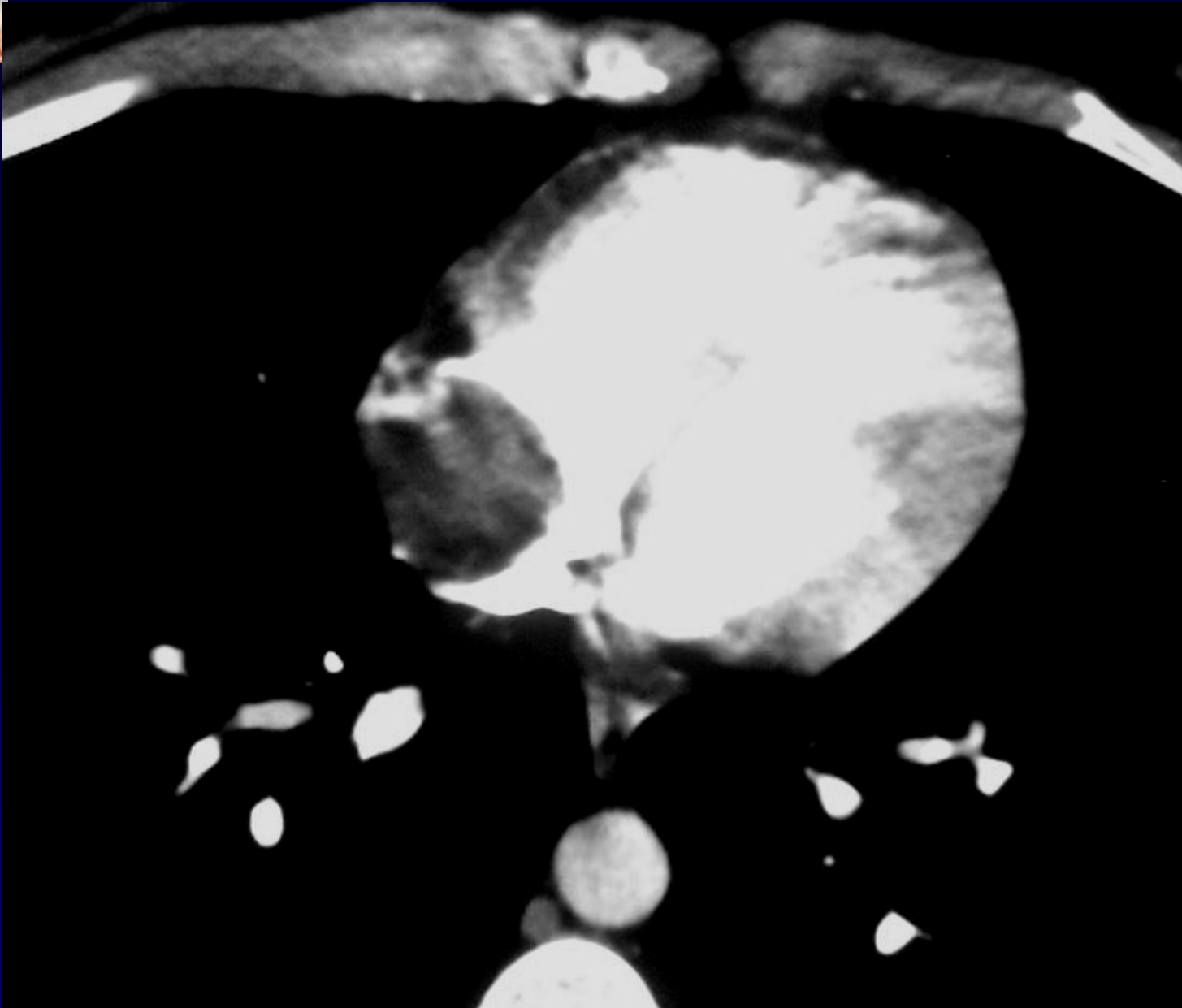
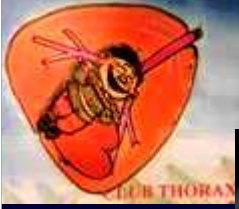

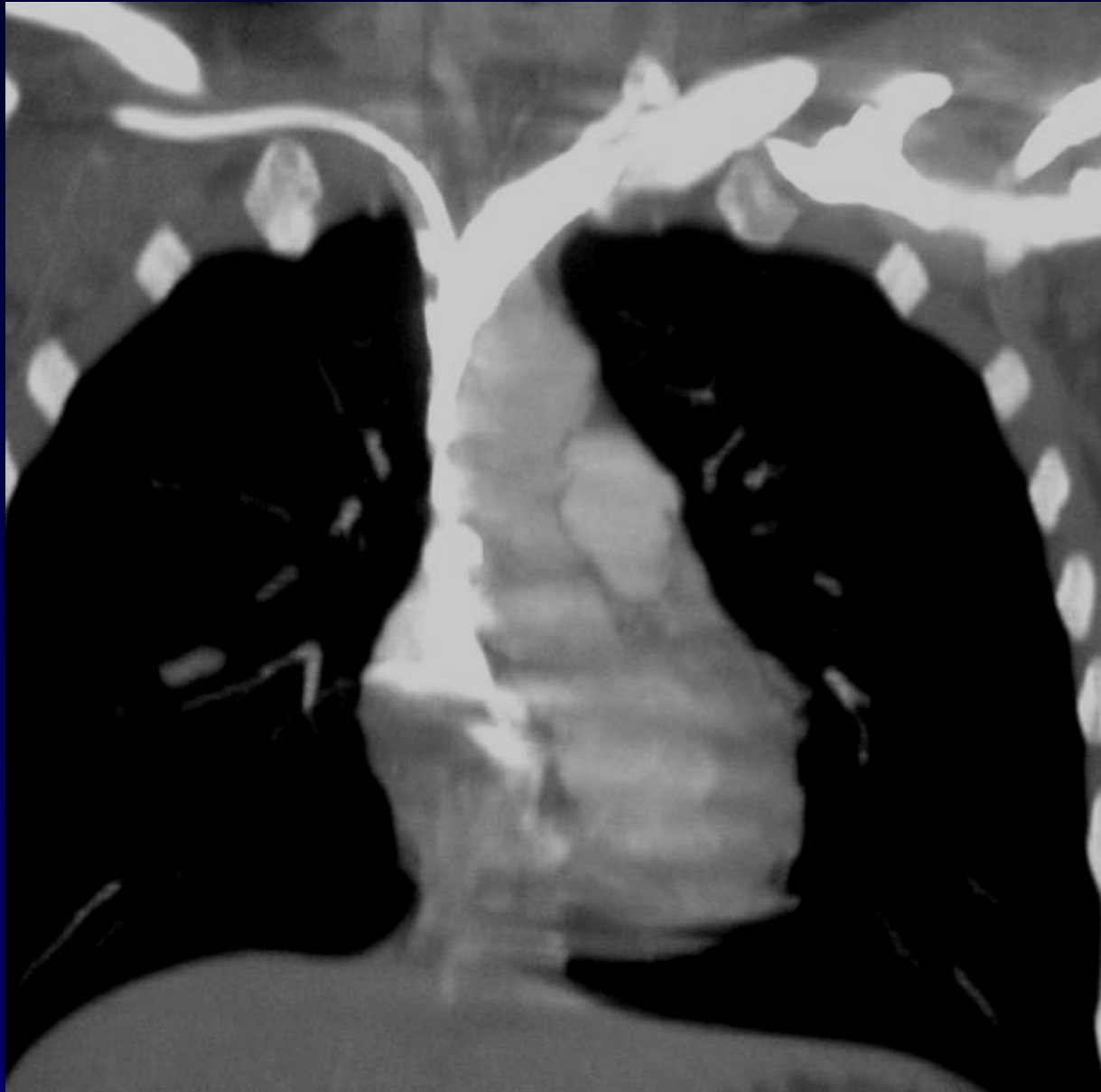


**Diagnostic ?**



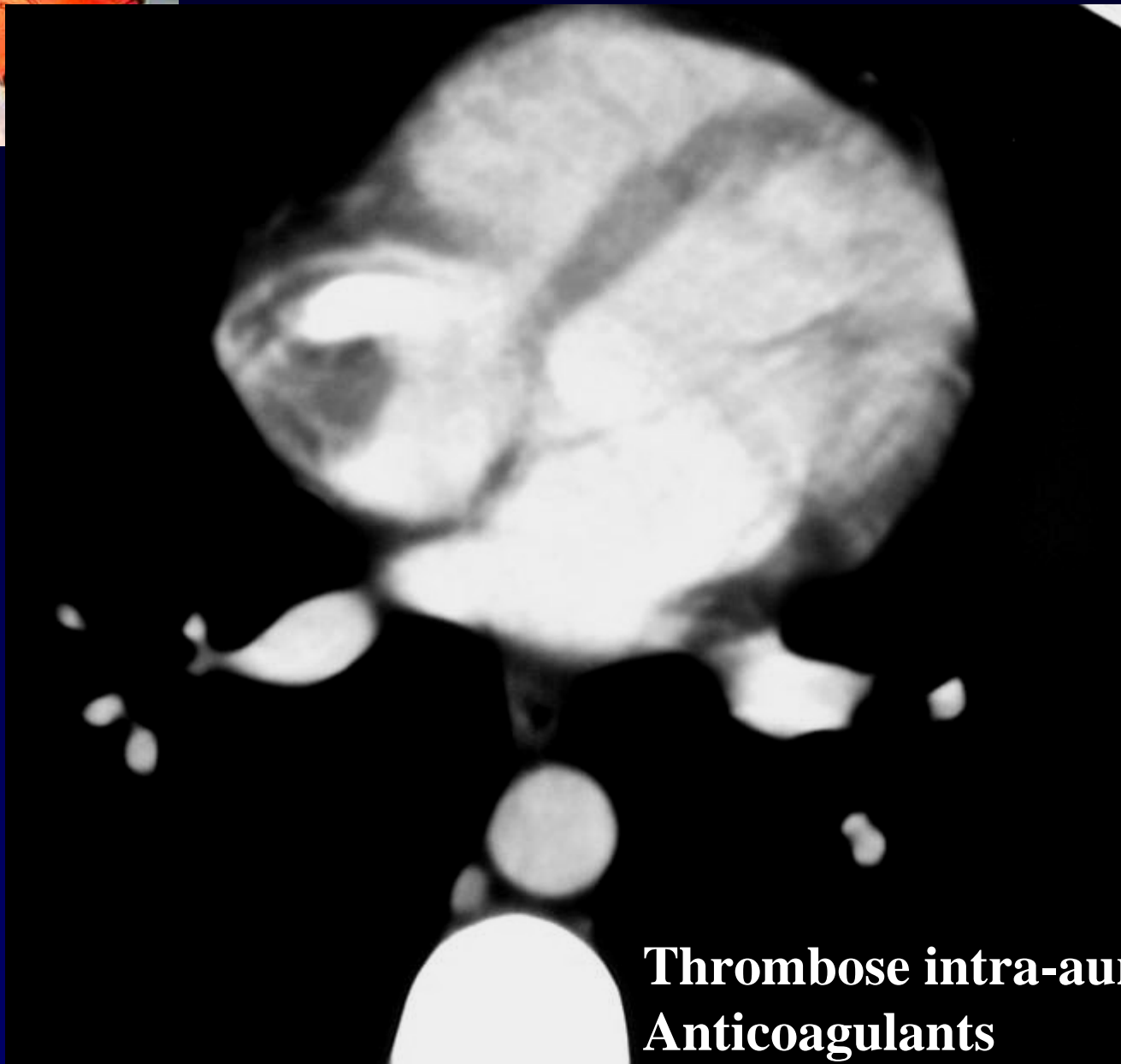
**Dispositif veineux implantable (DVI) trop long  
Extrémité du cathéter dans l'atrium droit**





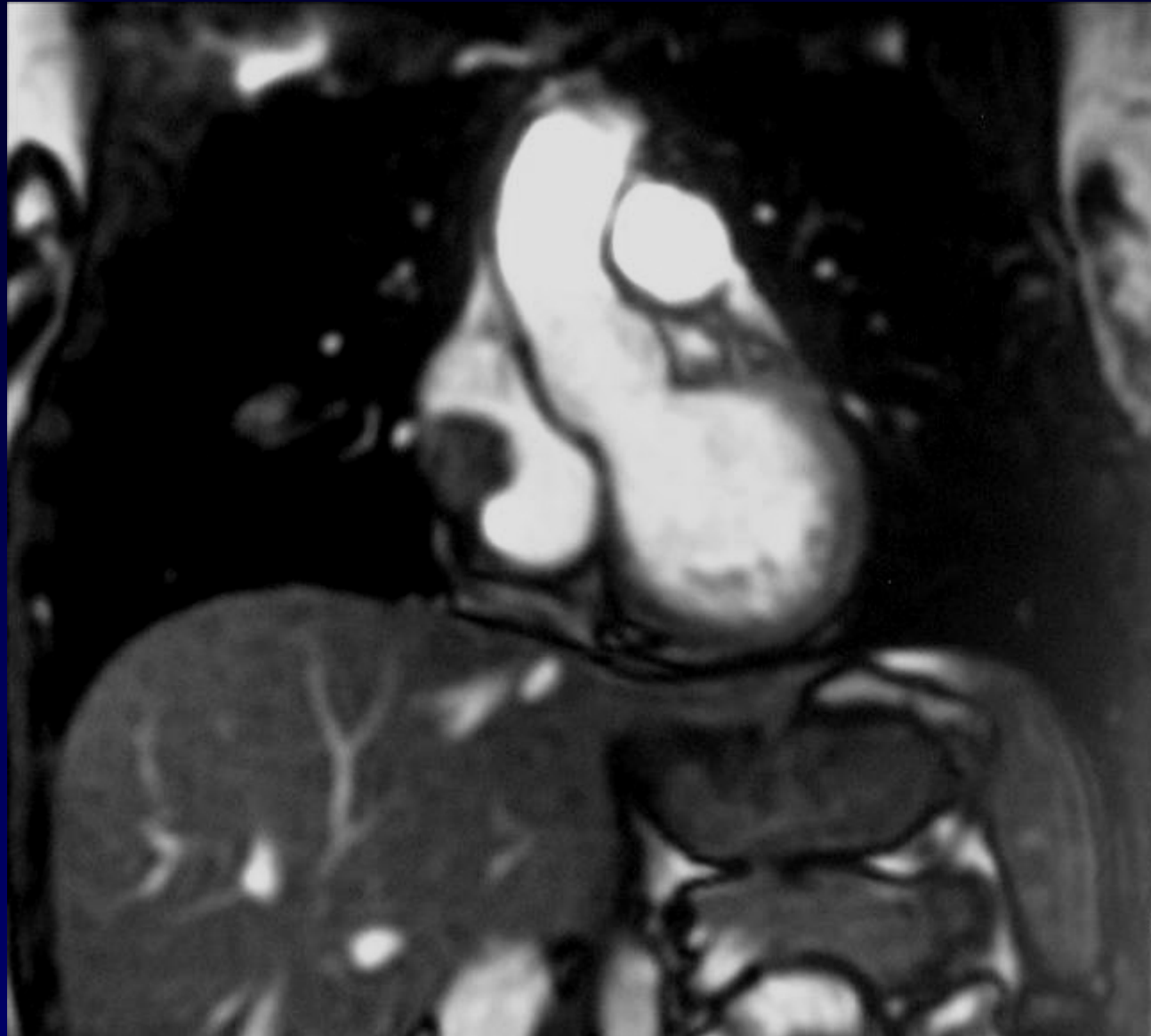


**Diagnostic ?**

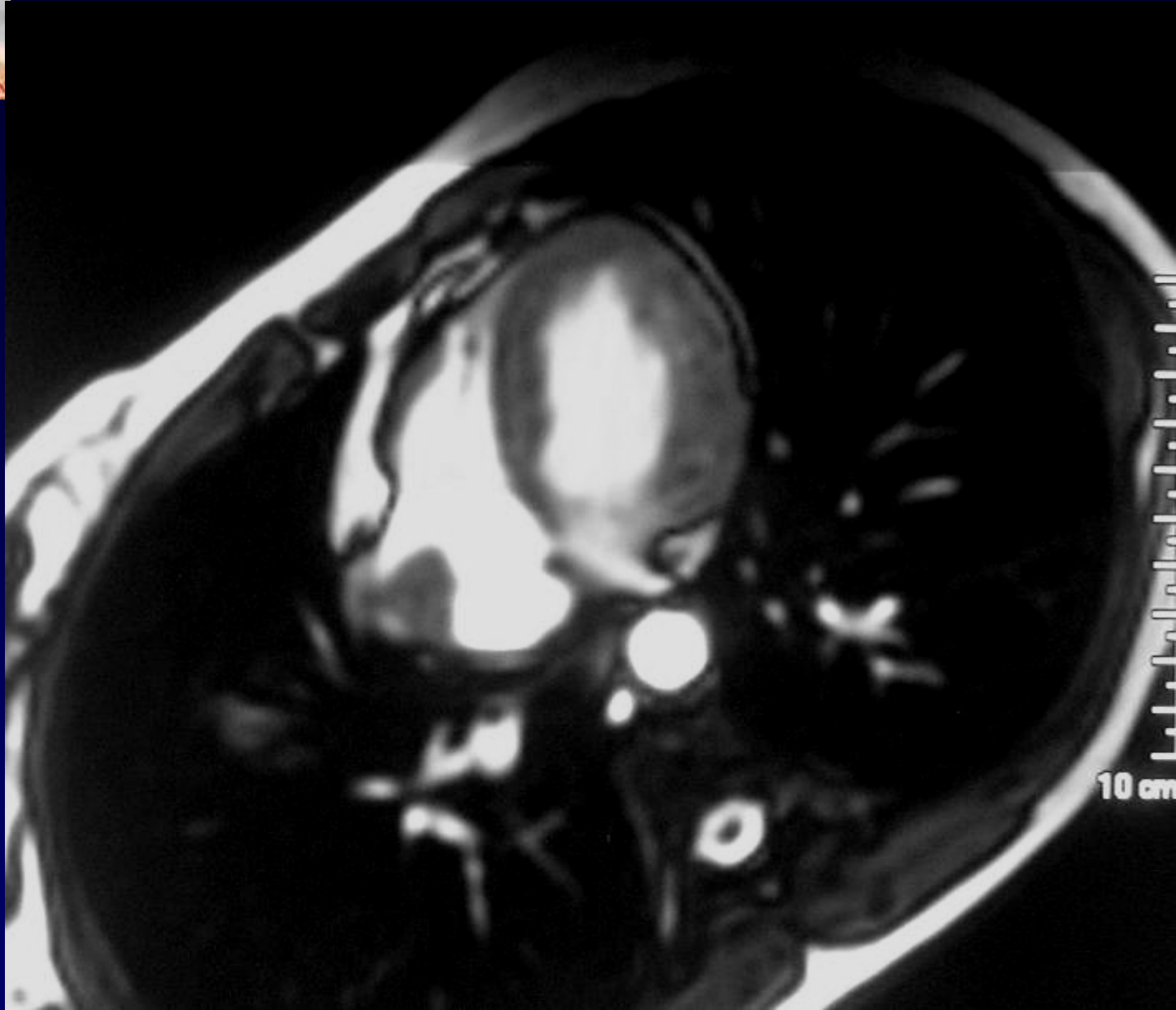
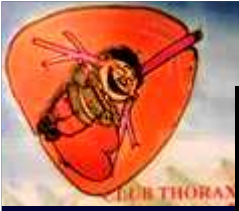
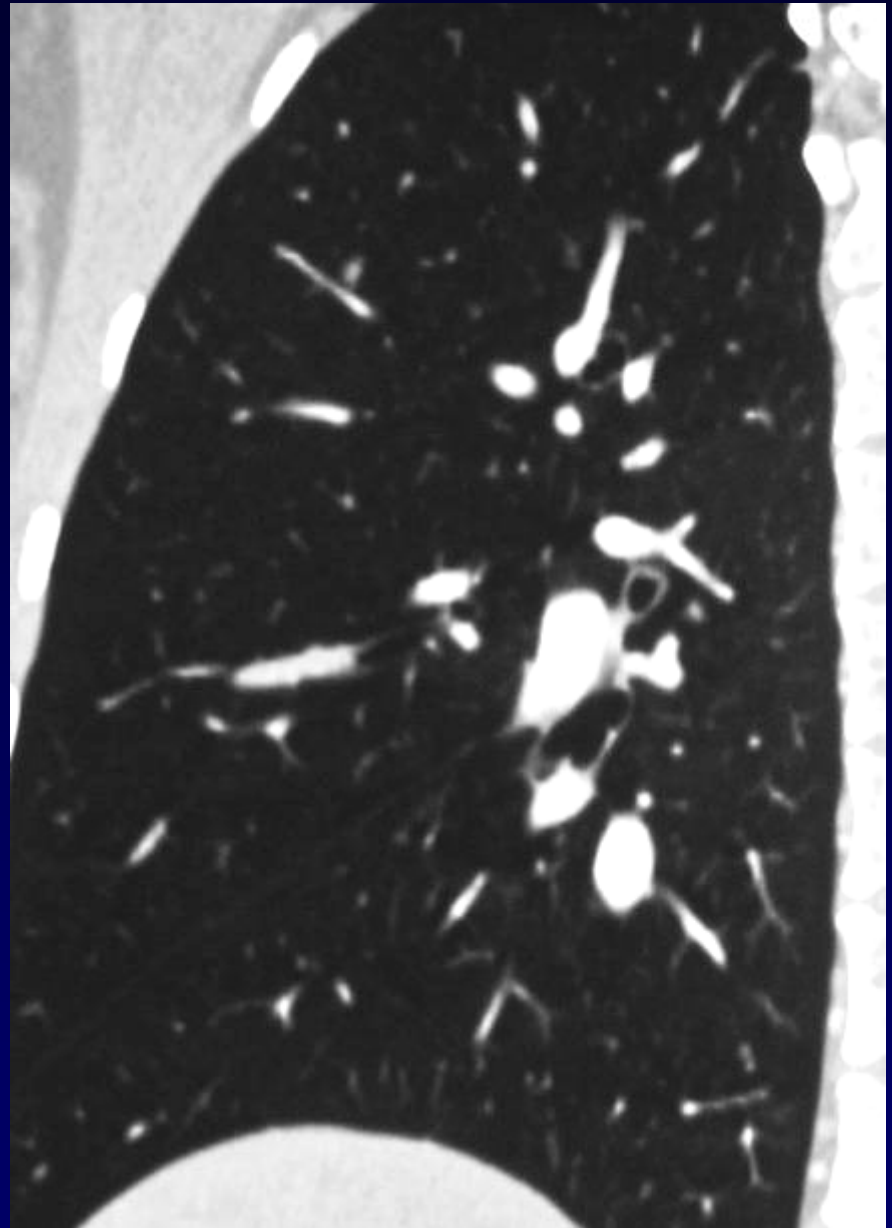
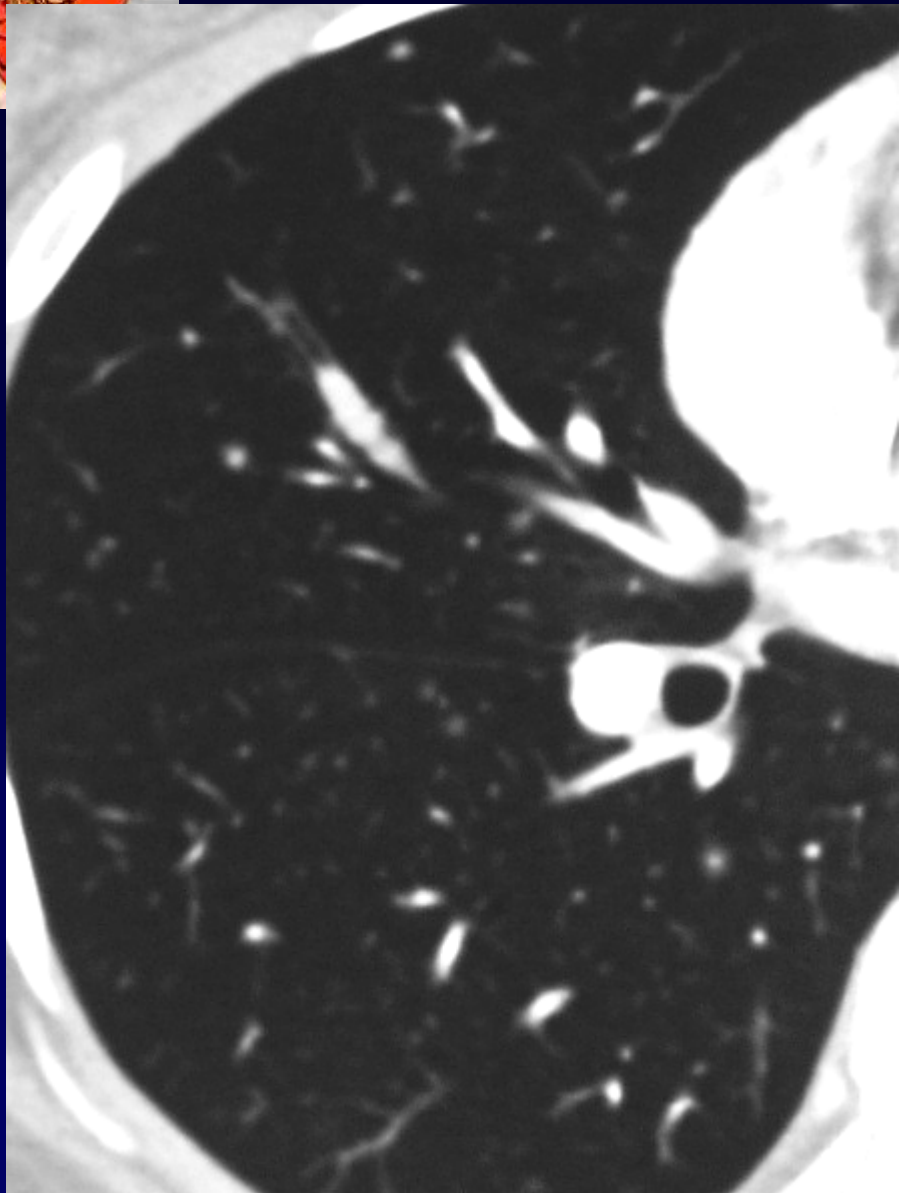
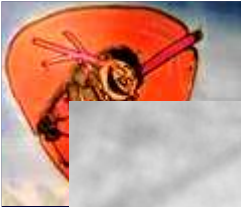**Thrombose intra-auriculaire sur le DVI  
Anticoagulants**

**TDM de contrôle à 2 mois**

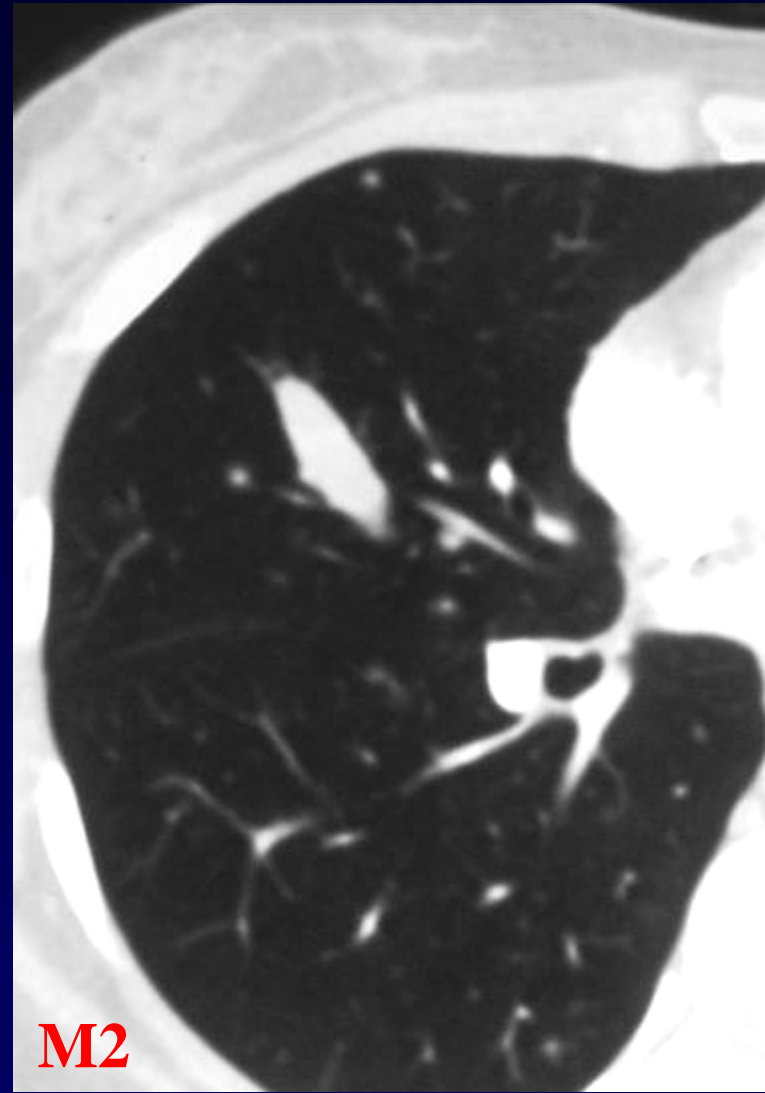
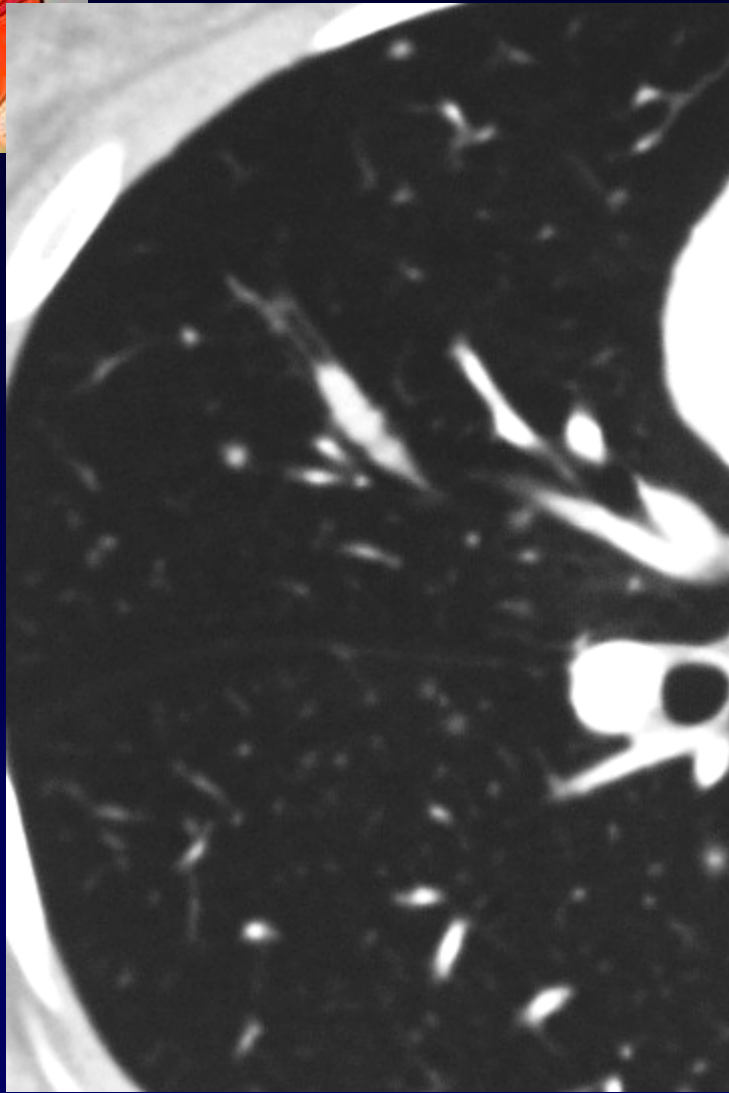
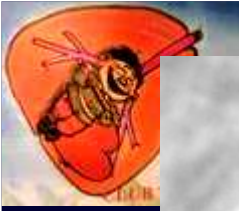

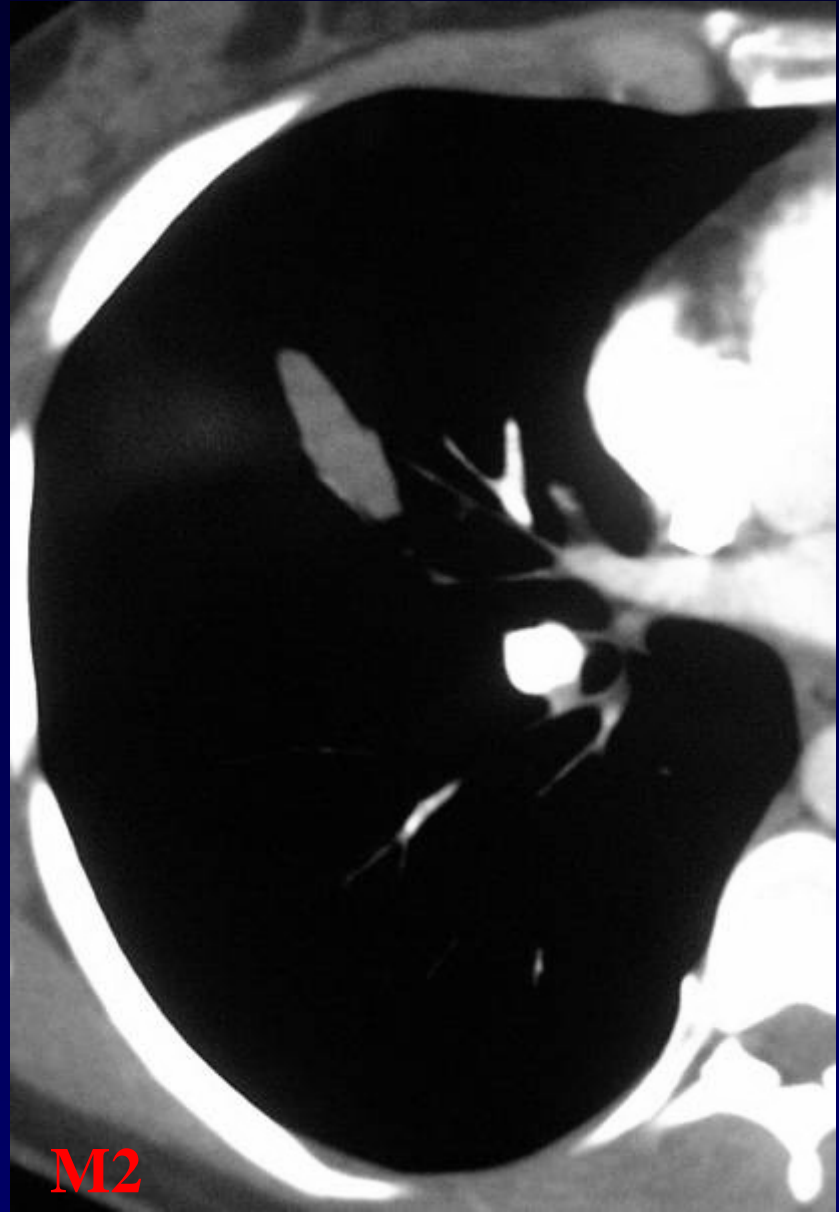
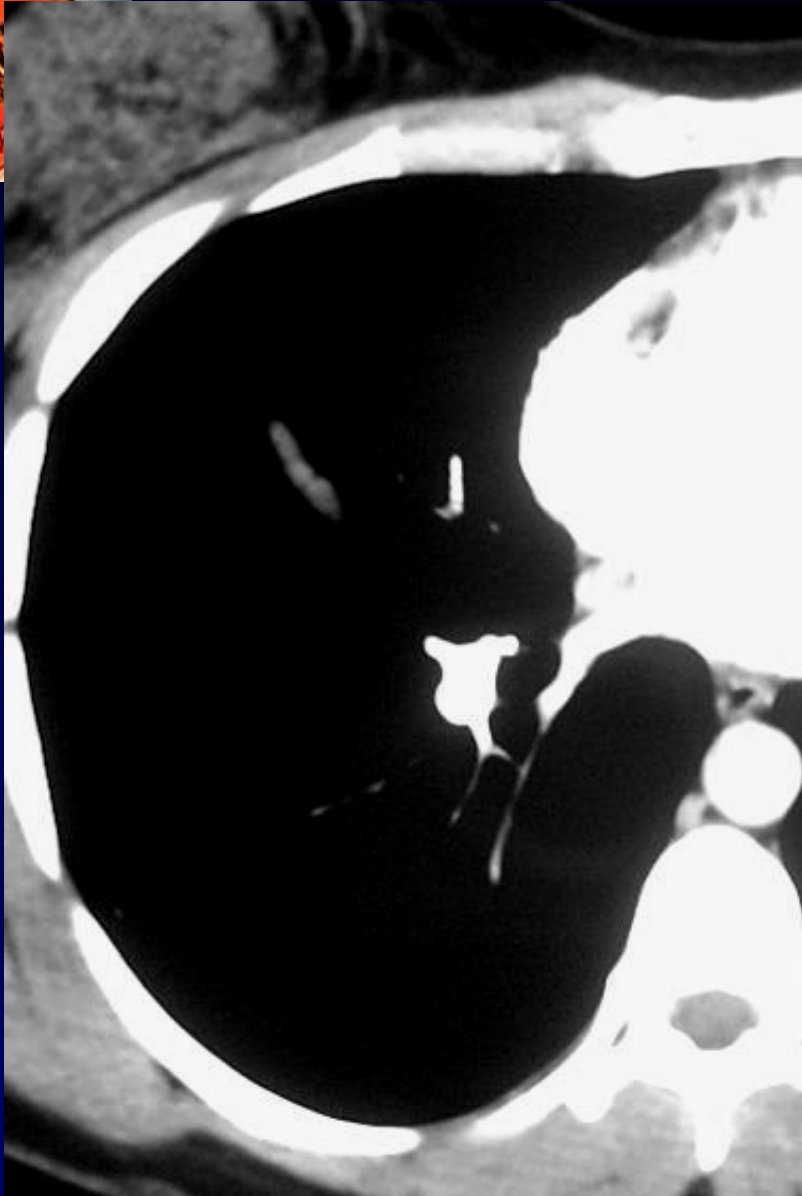
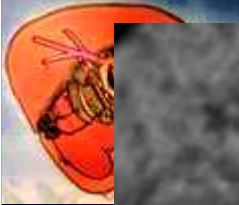**IRM cardiaque de contrôle à 2 mois**



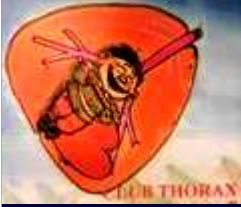

**Par ailleurs ?Extension tumorale endo-bronchique**





**Extension tumorale endo-bronchique en progression**



## **Diagnostic**

### **Mélanome métastatique**

- Thrombose veineuse sous clavière D**
- Thrombose OD sur DVI**
- Métastase endo-bronchique lobaire moyenne en progression**

**Codage : Poumon – Cardiovasculaire – Tumoral malin**